

Mesenteric mucinous cystadenoma: a diagnostic conundrum

Authors

- 1) Nidha Gaffoor, Senior Resident, Department of Pathology, Dr. Chandramma Dayananda Sagar Institute of Medical Education and Research, Harohalli, Ramanagara, Karnataka, India.
- 2) Archana Shetty, Associate Professor, Department of Pathology, Dr. Chandramma Dayananda Sagar Institute of Medical Education and Research, Harohalli, Ramanagara, Karnataka, India.
- 3) Aparna Muralidhar, Assistant Professor, Department of Pathology, Dr. Chandramma Dayananda Sagar Institute of Medical Education and Research, Harohalli, Ramanagara, Karnataka, India.
- 4) N. Nagendra Prasad, Professor & HOD, Department of OBG, Dr. Chandramma Dayananda Sagar Institute of Medical Education and Research, Harohalli, Ramanagara, Karnataka, India.

Corresponding Author : Dr. Aparna Muralidhar, Assistant Professor, Department of Pathology, Dr. Chandramma Dayananda Sagar Institute of Medical Education and Research, Harohalli, Ramanagara, Karnataka, India; Email : aparna1601@gmail.com

Manuscript submitted – 1st April 2021

Peer review completed – 4th June 2021

Accepted for Epub – 9th October 2021

Distributed under Attribution-Non Commercial – Share Alike 4.0 International (CC BY-NC-SA 4.0)

Abstract:

Mucinous cystic neoplasms (MCNs) can be of ovarian or extra-ovarian origin. They share a common pathway of development, but pathogenesis remains controversial. Case reports involving the mesentery as a primary tumour site are few in literature. We report a case of a 48 year old female who presented with abdominal pain. Ultrasound revealed an intraabdominal cystic mass probably of adnexal in origin under radiology. On laparotomy, the mass was seen arising from the mesentery and was suspected to be a mesenteric cyst. On histopathological examination, the cyst was diagnosed to be of neoplastic nature (mesenteric mucinous cystadenoma). MCNs of the mesentery remain asymptomatic until they attain a very large size. The awareness of this entity helps in considering this lesion in the differential diagnosis of mesenteric cysts. Complete surgical removal of the tumour without spillage is recommended, due to higher risk of recurrence and malignant transformation. The definitive diagnosis is based on histopathological examination which can exclude a borderline or malignant component, thereby helping in better patient management.

Keywords: Mucinous, cystadenoma, mesenteric, ultrasound.

Intra-abdominal cystic neoplasms are commonly of ovarian origin and can be classified into four major types: serous, clear cell, endometrioid, and mucinous. Incidence of the mucinous subtype is about 3% and they tend to be borderline or low grade, with an indolent course and favourable prognosis¹.

Mucinous cystic neoplasms (MCNs) can also arise at various extra-ovarian sites with equal distribution between sexes². Ovarian and extra-ovarian MCNs share a common pathway of development. The extraovarian MCNs have been described in pancreas, appendix, hepatobiliary tract and less commonly in retroperitoneum, paratesticular tissues, lung, breast, spleen, bowel and mesentery^{3,4}. They are usually incidental, or present with non-specific chronic symptoms like abdominal pain, distention, a palpable mass or gastrointestinal and urinary obstruction. Acute manifestation is often described in children and infants and may be associated with rupture, haemorrhage, torsion, infection or a complicated hernia³. Performing a thorough physical examination, radiological investigations and awareness of this entity are the key to a timely diagnosis^{5,6}. The most common subtype of extraovarian MCN is mucinous cystadenoma, which is typically large and multi-loculated⁷.

We report an interesting case of an extraovarian mucinous cystadenoma arising from the mesentery in a middle aged woman which was diagnosed clinically and radiologically as an adnexal cyst.

Case

A forty eight year old female, presented to the gynaecology OPD of our hospital with complaints of pain and fullness of abdomen since a week. On clinical examination, the abdomen was distended and a mass was palpable in the right lumbar region. Cervix and vagina were normal. Ultrasound (US) abdomen revealed a cystic lesion measuring 17.1 x 13 x 13 cm³ with low level internal echoes and incomplete septation, appearing to arise from the left adnexa. No mural nodule / vascularity was noted. Uterus was bulky with multiple intramural and subserosal fibroids. An impression of left adnexal cystic lesion with a differential diagnosis of paraovarian cyst/ paratubal cyst was given. (figure 1a). Routine laboratory investigations were within normal limits.

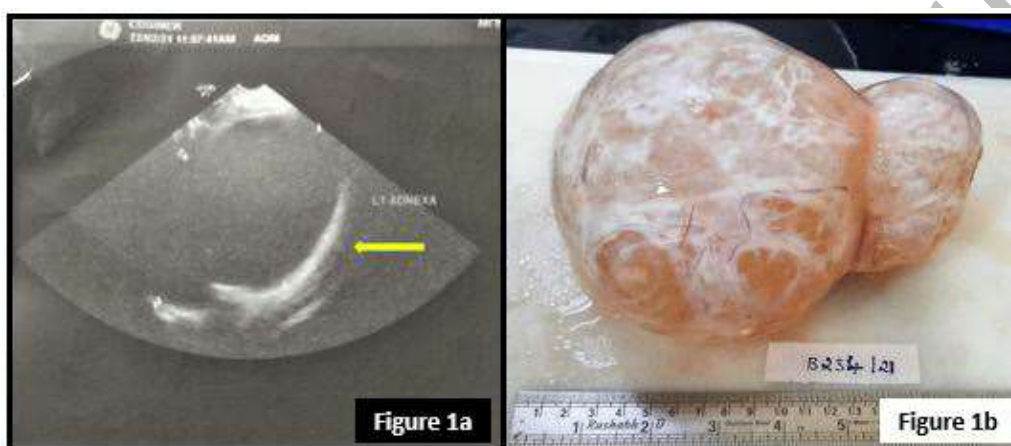


Figure 1: 1a - Ultrasound abdomen showing large cystic mass (arrow); 1b - Gross picture of the cystic mass.

The tumour marker, CA 125 done considering the possibility of cancer was within normal limits (15.44 U/ml). On laparotomy the cystic mass was seen arising from the mesentery. No adhesions were noted. The cyst was resected and sent en bloc for histopathological examination with a provisional diagnosis of a mesenteric cyst. Total abdominal hysterectomy was also performed for multiple fibroids. The cyst measured 18x13x8 cm³. External surface was smooth with congested vessels (figure 1b). On cutting open, it was unilocular with incomplete septations and exuded 600ml of mucinous fluid. The cyst wall was smooth with a thickness of 10mm. No solid areas or papillary excrescences were noted.

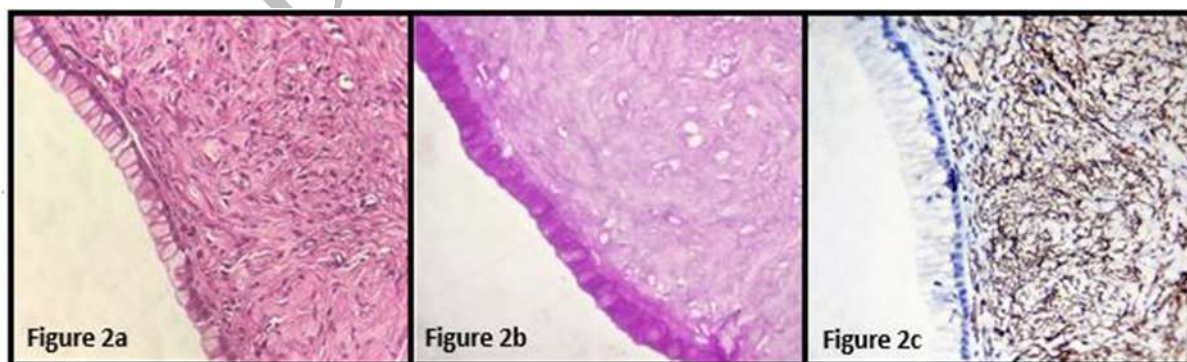


Figure 2: 2a - H&E stain showing an inner epithelial layer, consisting of columnar mucinous cells and an outer ovarian-like stromal layer (x400); 2b - Mucinous epithelium showing PAS with diastase positivity (x400); 2c - Ovarian like stromal cells showing strong SMA positivity (x400).

Microscopy revealed two distinct components: an inner epithelial layer, consisting of columnar mucinous cells and an outer ovarian-like stromal layer, composed of densely packed spindle shaped cells (figure 2a). There was no cellular atypia/ stratification of the epithelial layer nor evidence of ectopic ovarian tissue or teratomatous component. At few places the cyst showed a flattened mesothelial lining PAS with diastase highlighted the mucinous epithelium (figure 2b). Ovarian like stromal cells demonstrated a strong positivity for the immunohistochemistry (IHC) marker, smooth muscle actin (figure 2c). The overall features suggested a benign neoplasm of epithelial origin favouring a mucinous cystadenoma. The patient is recovering uneventfully and doing well on follow up.

Discussion

Intra-abdominal mucinous cystic neoplasms commonly arise from the ovaries. The determination of the tissue of origin becomes problematic, when they are large and seemingly involve both the mesentery and adnexa⁸. Mesenteric cysts are rare cystic masses that occur with a prevalence of 1/100000 to 1/250000 among adult hospital admissions⁵.

The first reported case of mesenteric cyst dates back to 1507 by Florentine anatomist, Benevieni and was described at an autopsy of an 8 year old boy². In 1880, Tillaux performed the first successful resection of a cystic tumour of the mesentery. The usual location of the cyst is the mesentery of the small intestine, commonly that of the ileum. Adult mesenteric cysts usually occur in the fifth decade⁵.

The aetiology of mesenteric cysts is variable. Four main theories have been proposed to explain the pathogenesis of extra-ovarian MCNs which are: mucinous metaplasia in pre-existing mesothelial cysts, invaginated peritoneum along the course of ovarian descent, coelomic metaplasia of epithelial cells and neoplastic differentiation of epithelial cells from a secondary extragenital mullerian system^{7,9}.

In 1950, Beahrs et al, classified mesenteric cysts into four categories: embryonic and developmental cysts, traumatic cysts, neoplastic cysts and infective and degenerative cysts. Later, Ros et al proposed a classification of five groups correlating with the radiological findings of the cysts, namely, lymphangiomas, enteric duplication cysts, enteric cysts, mesothelial cysts and non-pancreatic pseudocysts⁵. Proposed updated classification of mesenteric cystic lesions is based on the site of origin (lymphatic, mesothelial, enteric, urogenital, non - pancreatic pseudocysts). The classification also includes two separate categories of neoplastic and non neoplastic cystic lesions⁵. Our case falls under the category of neoplastic cysts - mucinous cystadenoma, incidence of which is rare.

Majority of the mesenteric cysts have no symptoms and are discovered incidentally, on USG or CT indicated for some other clinical conditions. Sometimes, they may manifest with symptoms such as diffuse abdominal pain, sensation of fullness or pressure in the abdomen, or due to other complications such as torsion, rupture, haemorrhage of cysts, herniation of bowel and obstruction². The patient in our case presented with similar non-specific symptoms and the intraabdominal cyst was picked up on scan along with multiple fibroids of the uterus.

A thorough physical examination and appropriate radiological studies are necessary for accurately diagnosing a mesenteric cyst. Diagnostic laparoscopy is another modality at the surgeon's disposal, if the location and characteristics of the lesion cannot be assessed adequately with radiological evaluation. Surgical excision is the mainstay of treatment for both, benign and malignant cysts. The surgical procedure depends on the lesion and extent of intrusion into the surrounding organs. Enucleation is adequate in majority of mesenteric cysts but, sometimes, bowel resection may be necessary when cysts are close to bowel structures or involve blood vessels that supply the bowel. Mesenteric cysts have a very low recurrence rate (0-13.6%) and have an excellent prognosis. The definitive diagnosis remains postoperative and therefore intra-operative frozen section need not be asked for unlike other cystic malignancies⁵. Laparoscopic resection has a high success rate with low incidence of postoperative complications. Though they are rare and difficult to diagnose prior to surgery, they must be considered in the differential diagnosis of a cystic lesion within the abdominal cavity.

The most common subtype of extraovarian MCN is mucinous cystadenoma, which is typically large, multi-loculated and filled with mucinous fluid. The cyst wall of MCNs is lined by mucin secreting flat, cuboidal and/or columnar epithelium associated with an underlying subepithelial ovarian like stroma (OLS). OLS shows histological features (spindle shaped cells and myofibroblastic proliferation) and immunohistochemistry (positivity for vimentin, α-

smooth muscle actin and desmin). Although, OLS is considered a requisite diagnostic criterion for MCNs, this is not always identified. Though the same was seen in our case, IHC was done to support the same. Both oestrogen and progesterone receptors are expressed in the nuclei of OLS cells⁷.

When differentiating mucinous from non-mucinous neoplasms and non-neoplastic cysts and evaluating their malignant potential, the following features may have a positive predictive but not pathognomonic value: patient age and tumour size, multilocularity, presence of calcifications, intracystic papillary projections or mural nodules, presence or lack of OLS, nuclei atypia, co-expression of (a6)-integrin and p53 immunoreactivity and/or high levels of CEA in the cyst fluid and positivity of other tumours markers (Ca 19-9, Ca-125, Ca 15-3). The risk of borderline and malignancy of mesenteric MCN in the literature is 48%².

On literature search, there are twenty documented cases of mesenteric MCNs prior to this report, eleven of which were located in the mesocolon^{2,10}. Eleven of them were reported as benign mucinous cystadenoma, five of them as borderline MCN, three as mucinous adenocarcinoma and one case recurred as malignant after incomplete resection of a benign mesenteric cyst. In most cases (including our case) the pre-operative imaging did not correlate with the exact tumour origin and was determined intraoperatively. Mesenteric MCN was reported in two male patients which questions the theory of ectopic ovarian tissue origin².

Conclusion

Mucinous cystic neoplasms of the mesentery remain asymptomatic until they attain a very large size. The definitive diagnosis is based on histological examination and requires awareness of this entity. Complete surgical removal of the tumour without spillage is recommended, due to higher risk of recurrence and malignant transformation in partially excised lesions.

References

1. Elias KM, Tsantoulis P, Tille JC, Vitonis A, Doyle LA, Hornick JL, et al. Primordial germ cells as a potential shared cell of origin for mucinous cystic neoplasms of the pancreas and mucinous ovarian tumors. *J Pathol*. 2018 Dec; 246(4): 459-69.
2. Barani T, Gotseva M, Polson A, Nath R, Mehra G, Lane G, et al. A giant mucinous borderline neoplasm of the mesentery misdiagnosed as an adnexal cyst - a case report and literature review. *Clin Obstet Gynecol Reprod Med*. 2017 Dec; 3(1): 1- 4.
3. Metaxas G, Tangalos A, Pappa P, Papageorgiou I. Mucinous cystic neoplasms of the mesentery: a case report and review of the literature. *World Journal of Surgical Oncology*. 2009 Dec; 7(1):1-8.
4. Bolukbas FF, Bolukbas C, Furuncuoglu Y, Tabandeh B, Saglam FY, Iyigun G, et al. Large abdominal cystic masses: Report of seven cases. *J Pak Med Assoc*. 2016 Feb 1; 66(2): 226-8.
5. Challa SR, Senapati D, Nulukurthi TK, Chinamilli J. Mucinous mesenteric cyst of the sigmoid mesocolon: a rare entity. *Case Reports*. 2016 Feb 23; 2016.
6. Badwe YR, Moje PD. Exploratory laparotomy in huge mucinous cystadenoma-a Single Case Study. *International Journal of AYUSH Case Reports*. 2019 Apr 3; 3(1): 80-5.
7. Tan A, Li R, Rafique M, Qin S, Pham T. A rare case of giant extra-ovarian mucinous cystadenoma arising from sigmoid mesocolon. *Journal of surgical case reports*. 2018 Mar; 2018(3): rjy038.
8. Lambert RG, Cervantes BYH, Gonzalez MR, Lopez DM, Edwin F. Large intra-abdominal mucinous cystic adenoma: is it of ovarian or mesenteric origin. *Pan Afr Med J*. 2020 Jun 25; 36:122.
9. Lung J, Gracey A, Rosales A, Bashover E, Sbar A, Nazim MH, et al. Laparoscopic excision of a retroperitoneal mucinous cystic neoplasm: A case report. *Int J Surg Case Rep*. 2019; 62: 27-30.

10. Sobnach S, Kloppers JC, Burmeister S, Locketz M, Roodt L, Thomson SR, et al. Primary seromucinous cystadenocarcinoma of the mesentery. South African Journal of Surgery. 2016; 54(3): 44-5.

Conflict of interest: None. **Disclaimer:** Nil.

Epub Ahead of Print